

A Systematic Review of Laser Resurfacing for Acne Scars

Michal Wen Sheue Ong and Dr. Saqib J Bashir. King's College London.

Abstract

Aim: To investigate the effectiveness of ablative and non-ablative Fractional Photothermolysis (FP) lasers for treating facial acne scars.

Method: A systematic literature search was performed using Boolean search method. This yielded 629 papers (PubMed= 250; Scopus= 370). 201 duplicates were removed. Of remaining 428 papers, 26 studies (13=ablative FP; 13=non-ablative FP) were selected using inclusion and exclusion criteria. Outcomes included subjective and objective assessment of scar appearance, pre and postoperative treatment, side effects, pain scores and patient satisfaction levels.

Results: Patients treated with either ablative or non-ablative FP experience a clinical improvement in scarring with histological evidence of new collagen and elastin formation in the upper and mid dermis. Clinical assessment showed an improvement range of 26-83% and 26-50% in ablative FP versus non-ablative FP respectively. 3D Optical Profiling Imaging showed significant improvement of skin surface smoothness and scar volume after 1-month of treatment but no further improvement at 3- and 6-months in ablative FP. Similarly, a 2-year clinical assessment follow-up study on ablative FP shows no further improvement of scar appearance after 3 months. Patients who undergo ablative FP laser experience erythema for 3-14 days which resolves by 12 weeks. Patients who opt for the non-ablative FP laser experience erythema between 1-3 days and this resolves within a week. A higher proportion of patients (up to 92.3%) who undertake ablative FP experience post-inflammatory hyperpigmentation (PIH) than those who have non-ablative FP (up to 13%). The maximum duration of PIH in ablative FP is up to 6 months whereas PIH in non-ablative FP lasts up to 1 week. A single case of herpes simplex was identified in ablative FP.

Ablative FP procedure can be more uncomfortable in comparison to non-ablative FP. Ablative pain score range from 5.90-8.10 (scale 1-10) and the non-ablative FP pain score range from 3.90-5.66 (scale 1-10). The percentage scar improvement for non-ablative FP depends on the number of treatments administered.

Conclusions: Ablative FP may be more efficacious in fewer treatments. However, patients experience longer down time and higher risk of getting PIH. This is also a relatively painful procedure in comparison to non-ablative FP.

Conflict of Interest: None

A Systematic Review of Laser Resurfacing for Acne Scars

Michal Wen Sheue Ong and Dr. Saqib J Bashir. King's College London.

Aim

To investigate the effectiveness of ablative and non-ablative Fractional Photothermolysis (FP) lasers for treating facial acne scars.

Methods

A systematic literature search was performed using Boolean search method. This yielded 629 papers (PubMed= 250; Scopus= 370). 201 duplicates were removed. Of remaining 428 papers, 26 studies (13=ablative FP; 13=non-ablative FP) were selected using inclusion and exclusion criteria. Outcomes included subjective and objective assessment of scar appearance, pre and postoperative treatment, side effects, pain scores and patient satisfaction levels.

A Systematic Review of Laser Resurfacing for Acne Scars

Michal Wen Sheue Ong and Dr. Saqib J Bashir. King's College London.

Inclusion and Exclusion Criteria

Studies reported on “acne scars” and “fractional photothermolysis” were **included**. Studies published between year-2003 to January 2011 were **included** in this review because this technology was only first introduced in 2003. Only human studies and English language articles were included. Case reports were **excluded** because this tends to overestimate the effects of treatment. Subjects with other skin conditions or scar types (e.g. hypertrophic, surgical scars) were **excluded**. Studies which did not state the overall improvement for acne scars, side effects or histological/ 3D optical profiling analysis were **excluded**.

All quantitative and qualitative data from each article meeting structured review framework were examined carefully for analysable variables and entered into a spreadsheet.

Completeness, quality and ambiguity of information was a primary criteria for inclusion, as where methodological similarities in trials.

A Systematic Review of Laser Resurfacing for Acne Scars

Michal Wen Sheue Ong and Dr. Saqib J Bashir. King's College London.

Pre and Post-operative Treatments

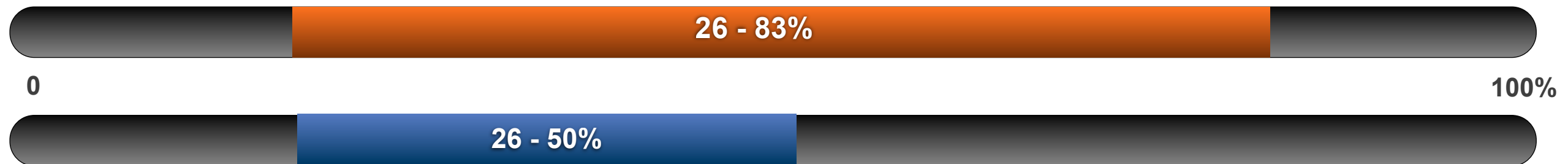
	Ablative FP	Non-Ablative FP
Pre-op Treatments	<ul style="list-style-type: none"> ✿ Topical anaesthetic cream (2.5% lidocaine hydrochloric acid and 2.5% prilocaine) ✿ Facial nerve blocks (1% lidocaine plus epinephrine) ✿ Analgesics ✿ Sedative medications 	<ul style="list-style-type: none"> ✿ Not necessary ✿ Could use topical anaesthetic cream
Post-op Treatments	<ul style="list-style-type: none"> ✿ Antiviral ✿ Antibiotic ✿ Avoid sun exposure ✿ Use sun screen ✿ 10mg prednisolone ✿ Mild cleanser ✿ Non-comedogenic moisturising cream 	<ul style="list-style-type: none"> ✿ (Antiviral) ✿ (Antibiotic) ✿ Avoid sun exposure ✿ Use sun screen ✿ (10mg prednisolone) ✿ Mild cleanser ✿ Non-comedogenic moisturising cream

A Systematic Review of Laser Resurfacing for Acne Scars

Michal Wen Sheue Ong and Dr. Saqib J Bashir. King's College London.

Results : Improvement Range

 Ablative FP  Non-ablative FP



Patients treated with either ablative or non-ablative FP experience a clinical improvement in scarring with histological evidence of new collagen and elastin formation in the upper and mid dermis.

Clinical assessment showed an improvement range of 26-83% and 26-50% in ablative FP versus non-ablative FP respectively. 3D Optical Profiling Imaging showed significant improvement of skin surface smoothness and scar volume after 1-month of treatment but no further improvement at 3- and 6-months in ablative FP. Similarly, a 2-year clinical assessment follow-up study on ablative FP shows no further improvement of scar appearance after 3 months.

The percentage scar improvement for non-ablative FP depends on the number of treatments administered.

A Systematic Review of Laser Resurfacing for Acne Scars

Michal Wen Sheue Ong and Dr. Saqib J Bashir. King's College London.

Results : Erythema

 Ablative FP  Non-ablative FP




Patients who undergo ablative FP laser experience erythema for 3-14 days which resolves by 12 weeks. Patients who opt for the non-ablative FP laser experience erythema between 1-3 days and this resolves within a week.

A Systematic Review of Laser Resurfacing for Acne Scars

Michal Wen Sheue Ong and Dr. Saqib J Bashir. King's College London.

Results : Proportion of Subjects with PIH*

 Ablative FP  Non-ablative FP



A higher proportion of patients (0-92.3%*) who undertake ablative FP experience PIH than those who have non-ablative FP (0-13%).

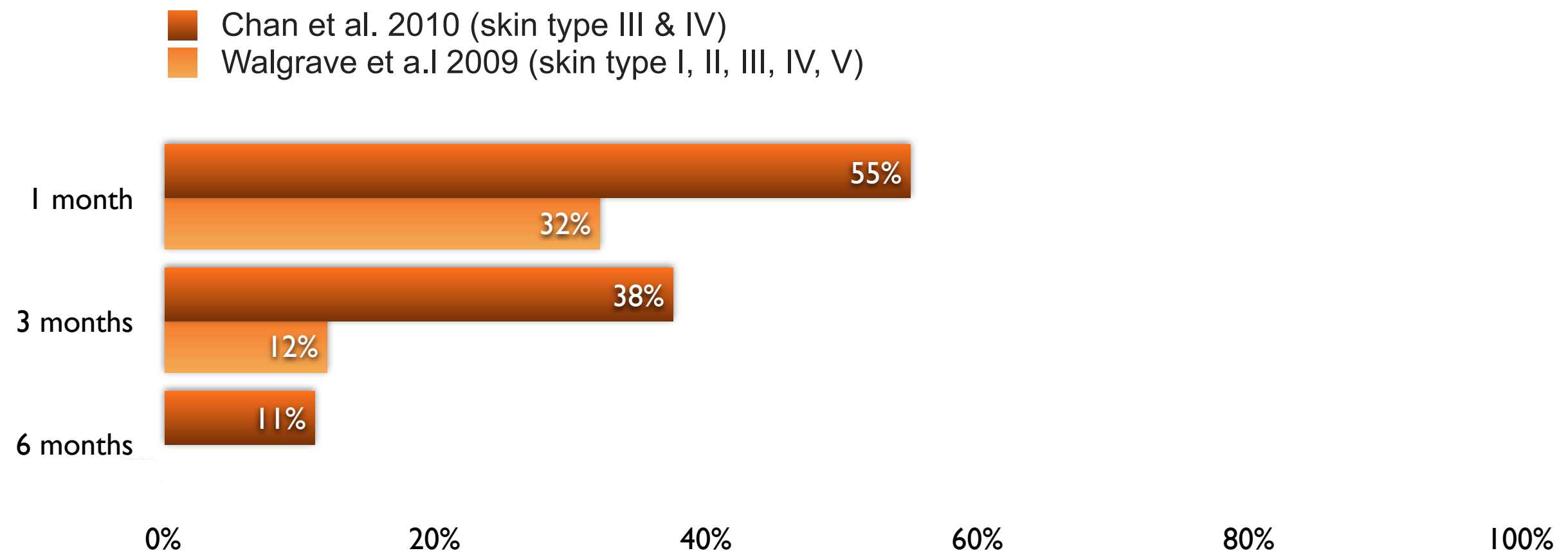
*PIH - post-inflammatory hyperpigmentation.

**92.3% limited to individuals with skin type IV ¹⁰

A Systematic Review of Laser Resurfacing for Acne Scars

Michal Wen Sheue Ong and Dr. Saqib J Bashir. King's College London.

Results : Proportion of Subjects with PIH Over Time, Post CO₂ Ablative FP, 10600nm (%)




A Systematic Review of Laser Resurfacing for Acne Scars

Michal Wen Sheue Ong and Dr. Saqib J Bashir. King's College London.

Results : Maximum Duration of PIH

 Ablative FP  Non-ablative FP



The maximum duration of PIH in ablative FP is up to 6 months whereas PIH in non-ablative FP lasts up to 1 week.


Average duration in skin type IV was 5 weeks (2-16 weeks).¹⁰

A Systematic Review of Laser Resurfacing for Acne Scars

Michal Wen Sheue Ong and Dr. Saqib J Bashir. King's College London.

Results : Pain Score

 Ablative FP  Non-ablative FP



Ablative pain score range from 5.90-8.10 (scale 1-10) and the non-ablative FP pain score range from 3.90-5.66 (scale 1-10).

Non-ablative FP: The average pain scores was higher in darker skin than lighter skin. ²⁵

- skin type V & VI, score 5.66 (scale 1-10);
- skin type IV 4.16 (scale 1-10)

A Systematic Review of Laser Resurfacing for Acne Scars

Michal Wen Sheue Ong and Dr. Saqib J Bashir. King's College London.

Conclusions

Ablative FP may be more efficacious in fewer treatments. However, patients experience longer down time and higher risk of getting PIH, particularly in darker skin types. However, this needs further investigation. Ablative FP is also a relatively painful procedure in comparison to non-ablative FP.

A Systematic Review of Laser Resurfacing for Acne Scars

Michal Wen Sheue Ong and Dr. Saqib J Bashir. King's College London.

References

1. CR. Fractional Laser Skin Resurfacing Information. 2011 [cited; Available from: <http://www.consultingroom.com/Treatments/Fractional-Laser-Skin-Resurfacing>]
2. Cho SB, Lee SJ, Kang JM, Kim YK, Chung WS, Oh SH. The efficacy and safety of 10,600-nm carbon dioxide fractional laser for acne scars in Asian patients. *Dermatol Surg*. 2009a; 35(12): 1955-61.
3. Chan HHL, Manstein D, Yu CS, Shek S, Kono T, Wei WI. The prevalence and risk factors of post-inflammatory hyperpigmentation after fractional resurfacing in Asians. *Lasers in Surgery and Medicine*. 2007; 39(5): 381-5.4.
4. Tanzi EL, Wanitphakdeedecha R, Alster TS. Fraxel laser indications and long-term follow-up. *Aesthet Surg J*. 2008; 28(6): 675-8; discussion 9-80.
5. Chan NP, Ho SG, Yeung CK, Shek SY, Chan HH. Fractional ablative carbon dioxide laser resurfacing for skin rejuvenation and acne scars in Asians. *Lasers Surg Med*. 2010; 42(9): 615-23.
6. Chapas AM, Brightman L, Sukal S, Hale E, Daniel D, Bernstein LJ, et al. Successful treatment of acneiform scarring with CO2 ablative fractional resurfacing. *Lasers Surg Med*. 2008; 40(6): 381-6.
7. Jung JY, Lee JH, Ryu DJ, Lee SJ, Bang D, Cho SB. Lower-fluence, higher-density versus higher-fluence, lower-density treatment with a 10,600-nm carbon dioxide fractional laser system: a split-face, evaluator-blinded study. *Dermatol Surg*. 2010; 36(12): 2022-9.
8. Katz B. Efficacy of a new fractional CO2 laser in the treatment of photodamage and acne scarring. *Dermatol Ther*. 2010; 23(4): 403-6.
9. Kim S, Cho KH. Clinical trial of dual treatment with an ablative fractional laser and a nonablative laser for the treatment of acne scars in Asian patients. *Dermatol Surg*. 2009; 35(7): 1089-98.
10. Manuskiatti W, Triwongwanat D, Varothai S, Eimpunth S, Wanitphakdeedecha R. Efficacy and safety of a carbon-dioxide ablative fractional resurfacing device for treatment of atrophic acne scars in Asians. *J Am Acad Dermatol*. 2010; 63(2): 274-83.
11. Ortiz AE, Tremaine AM, Zachary CB. Long-term efficacy of a fractional resurfacing device. *Lasers Surg Med*. 2010; 42(2): 168-70.
12. aTrelles MA, Shohat M, Urdiales F. Safe and Effective One-Session Fractional Skin Resurfacing Using a Carbon Dioxide Laser Device in Super-Pulse Mode: A Clinical and Histologic Study. *Aesthetic Plast Surg*. 2010.
13. Walgrave SE, Ortiz AE, MacFalls HT, Elkeeb L, Truitt AK, Tournas JA, et al. Evaluation of a novel fractional resurfacing device for treatment of acne scarring. *Lasers Surg Med*. 2009; 41(2): 122-7.
14. Wang YS, Tay YK, Kwok C. Fractional ablative carbon dioxide laser in the treatment of atrophic acne scarring in Asian patients: a pilot study. *J Cosmet Laser Ther*. 2010; 12(2): 61-4.
15. Cho SB, Lee SJ, Cho S, Oh SH, Chung WS, Kang JM, et al. Non-ablative 1550-nm erbium-glass and ablative 10 600-nm carbon dioxide fractional lasers for acne scars: a randomized split-face study with blinded response evaluation. *J Eur Acad Dermatol Venereol*. 2010; 24(8): 921-5.
16. Deng H, Yuan D, Yan C, Lin X, Ding X. A 2940 nm fractional photothermolysis laser in the treatment of acne scarring: a pilot study in China. *J Drugs Dermatol*. 2009; 8(11): 978-80. 17.
17. Tay YK, Kwok C. Minimally ablative erbium:YAG laser resurfacing of facial atrophic acne scars in Asian skin: a pilot study. *Dermatol Surg*. 2008; 34(5): 681-5.
18. Alster TS, Tanzi EL, Lazarus M. The use of fractional laser photothermolysis for the treatment of atrophic scars. *Dermatol Surg*. 2007; 33(3): 295-9.
19. Cho SB, Lee JH, Choi MJ, Lee KY, Oh SH. Efficacy of the fractional photothermolysis system with dynamic operating mode on acne scars and enlarged facial pores. *Dermatol Surg*. 2009b; 35(1): 108-14.
20. Chrastil B, Glaich AS, Goldberg LH, Friedman PM. Second-generation 1,550-nm fractional photothermolysis for the treatment of acne scars. *Dermatol Surg*. 2008; 34(10): 1327-32.
21. Hasegawa T, Matsukura T, Mizuno Y, Suga Y, Ogawa H, Ikeda S. Clinical trial of a laser device called fractional photothermolysis system for acne scars. *J Dermatol*. 2006; 33(9): 623-7.
22. Hu S, Chen MC, Lee MC, Yang LC, Keoprasom N. Fractional resurfacing for the treatment of atrophic facial acne scars in asian skin. *Dermatol Surg*. 2009; 35(5): 826-32.
23. Kim HJ, Kim TG, Kwon YS, Park JM, Lee JH. Comparison of a 1,550 nm Erbium: glass fractional laser and a chemical reconstruction of skin scars (CROSS) method in the treatment of acne scars: a simultaneous split-face trial. *Lasers Surg Med*. 2009; 41(8): 545-9.
24. Lee HS, Lee JH, Ahn GY, Lee DH, Shin JW, Kim DH, et al. Fractional photothermolysis for the treatment of acne scars: a report of 27 Korean patients. *J Dermatolog Treat*. 2008; 19(1): 45-9.
25. Mahmoud BH, Srivastava D, Janiga JJ, Yang JJ, Lim HW, Ozog DM. Safety and efficacy of erbium-doped yttrium aluminum garnet fractionated laser for treatment of acne scars in type IV to VI skin. *Dermatol Surg*. 2010; 36(5): 602-9.
26. Hedelund L, Moreau KE, Beyer DM, Nymann P, Haedersdal M. Fractional nonablative 1,540-nm laser resurfacing of atrophic acne scars. A randomized controlled trial with blinded response evaluation. *Lasers Med Sci*. 2010; 25(5): 749-54.
27. Yoo KH, Ahn JY, Kim JY, Li K, Seo SJ, Hong CK. The use of 1540 nm fractional photothermolysis for the treatment of acne scars in Asian skin: A pilot study. *Photodermatology Photoimmunology and Photomedicine*. 2009; 25(3): 138-42.